



# PICC-related upper deep venous thrombosis in patients with hematological malignancies. Management of anticoagulant therapy according to the platelet count

Maria Cristina Scamuffa<sup>1</sup> · Salvatore Giacomo Morano<sup>1</sup> · Alessandra Serrao<sup>1</sup> · Antonella Bruzzese<sup>1</sup> · Francesca Stocchi<sup>1</sup> · Cristina Santoro<sup>1</sup> · Federico Vozella<sup>1</sup> · Roberto Latagliata<sup>1</sup> · Antonio Chistolini<sup>1</sup> 

© Springer Science+Business Media, LLC, part of Springer Nature 2020

## Abstract

Peripherally inserted central catheters (PICCs) for central venous access are frequently used in patients with hematological malignancies. Their use may be complicated by upper extremity deep venous thrombosis (UEDVT). Additionally, hematological patients are frequently thrombocytopenic and the optimal management of UEDVT in patients with thrombocytopenia is challenging and poorly standardized. We retrospectively analyzed 50 adult patients affected by hematological malignancies who presented a PICC-associated UEDVT. UEDVT treatment was compared in 3 groups: patients with a platelet count  $\geq 50 \times 10^9/l$  (group 1) who underwent a therapeutic dose of low molecular weight heparin (LMWH) or fondaparinux 7.5 mg; patients with a platelet count  $< 50 \times 10^9/l$  and  $\geq 30 \times 10^9/l$  (group 2) who were treated with a 50% reduced dose of LMWH or fondaparinux 5 mg; patients with platelets  $< 30 \times 10^9/l$  (group 3) were observed and treated with anticoagulants when the count was  $> 30 \times 10^9/l$ . At the onset of thrombosis, 36 patients were in group 1, 8 in group 2 and 6 in group 3. We observed no hemorrhagic or thrombotic complications related to the anticoagulant therapy; length of treatment was comparable between groups 1 and 2 (51 days group 1 vs 50 days group 2). Reduced doses of LMWH or fondaparinux may represent a safe and effective therapeutic approach in patients with moderate thrombocytopenia ( $< 50 \times 10^9/l$  and  $\geq 30 \times 10^9/l$ ) and a PICC-associated UEDVT.

**Keywords** PICC · Thrombosis · Thrombocytopenia · Anticoagulant therapy

## Highlights

- Anticoagulant treatment in patients with hematological malignancies is still challenging due to frequent presence of thrombocytopenia.
- In case of PICC related upper extremity deep vein thrombosis, low molecular weight heparin is the standard anticoagulant therapy and its dosage can be adjusted on the basis of platelets count.
- In patients with a platelet count between  $50 \times 10^9/l$  and  $30 \times 10^9/l$  the use of reduced doses of low molecular

weight heparin or fondaparinux may be safe and effective in the treatment of PICC related upper extremity deep vein thrombosis.

## Introduction

Peripherally inserted central catheters (PICCs) for central venous access came into common use in the mid-2000s. Their use is nowadays a routine practice especially in oncology and hematology for the infusion of anti-neoplastic agents and supportive therapies including transfusions; in the setting of hematological malignancies, PICCs are also used for the infusion of stem cells in the setting of autologous and allogeneic transplants.

PICCs are easy to insert and remove. They can be easily used outside of the hospital and the risk of early complications and bleedings is low [1, 2], also in patients with severe thrombocytopenia. They are well tolerated by patients and

✉ Antonio Chistolini  
antonio.chistolini@uniroma1.it

<sup>1</sup> Hematology, Department of Translational and Precision Medicine, Sapienza University, Via Benevento 6, 00161 Rome, Italy

less expensive than other central venous catheters (CVCs) [3]. However, their use may be complicated by an upper extremity deep venous thrombosis (UEDVT). A review of 11 studies based on almost 4000 patients showed that PICCs were associated with a 2.6-fold greater risk of thrombosis than other types of CVC ( $p < 0001$ ) [2, 4]. Cancer patients are particularly susceptible to this complication due to the hypercoagulable state related to the neoplasm itself. Despite the frequent presence of thrombocytopenia, patients with hematological malignancies are at an increased risk of venous thromboembolism (VTE), with an incidence ranging between 2 and 18% compared to 0.6–7.8% in other malignancies [5–7]. The traditional management of deep venous thrombosis (DVT) in cancer has been based on unfractionated or low molecular weight heparin (LMWH) or on fondaparinux preferred to oral anticoagulants because of a lower bleeding risk [8, 9]. The optimal treatment of VTE in patients with thrombocytopenia remains challenging. Only 3 observational studies have reported data on the use of anticoagulants in the management of VTE in patients with hematological malignancies and platelets  $< 50 \times 10^9/l$  [10–12]. Aim of our study was to retrospectively evaluate in patients with hematological malignancies who developed an UEDVT the efficacy, in terms of UEDVT relapses, of different doses of LMWH or fondaparinux modulated according to the platelet count and the safety in terms of hemorrhagic complications. We also evaluated differences in therapy length between patients treated with therapeutic doses and reduced doses of LMWH or fondaparinux and between patients carrying a Groshong or a Power PICC.

## Patients and methods

This is a retrospective single center study involving a cohort of patients with hematological malignancies who presented an UEDVT. Between July 2010 and June 2018, 1920 PICCs have been implanted at our Center and 50 patients have experienced an UEDVT. Patients were divided into three groups based on the platelet count at the time of UEDVT: group 1 with a platelet count  $\geq 50 \times 10^9/l$ ; group 2 patients with a platelet count  $< 50 \times 10^9/l$  and  $\geq 30 \times 10^9/l$ ; group 3 with a platelet count  $< 30 \times 10^9/l$ . Two types of catheters were used in relation to the type and duration of the planned treatment: Groshong PICC 4 Fr Bard and Power PICC 5 Fr Bard (Bard Access Systems, Salt Lake City, UT). After local anesthesia, PICCs were inserted in the superior vena cava 2 cm before the entrance in the right atrium, through the basilic or brachial veins under ultra-sound guidance. UEDVT diagnosis was ultrasound-based and defined by the following criteria: vein incompressibility, absence of spontaneous flow, turbulent flow and presence of thrombotic material in the venous lumen. Once thrombosis was diagnosed, anticoagulation was started immediately. All outpatients were checked weekly

in order to verify the UDEVt evolution and bleeding complications during the anticoagulant therapy. Inpatients were instead monitored daily. Ultrasound control was performed 15 days after diagnosis and then monthly until resolution of thrombosis. All ultrasound exams were performed at our Institution by the same echographic team. Statistical analyses were based on the SPSS version 19 software (SPSS, Armonk, NY).

## Anticoagulant therapy

Patients were treated with LMWH or fondaparinux. LMWH was the first choice in patients with more fluctuating platelet counts, ondaparinux in patients with a stable value. Group 1 started a therapeutic dose of LMWH (100 U/kg twice a day) or fondaparinux (7.5 mg/day); group 2 was treated with a 50% reduced dose of LMWH (100 U/kg/day) or fondaparinux (5 mg/day). In group 3, our general approach was observation or platelet transfusion to allow anticoagulation. LMWH or fondaparinux doses were adjusted according to platelet count. Anticoagulant therapy was continued until thrombosis resolution.

## Results

Fifty of the 1920 patients witnessed a PICC-associated UEDVT during the period between July 2010 and June 2018: the incidence of UEDVT was 0.32% case/year. Twenty-nine were males and 21 females. The median age was 53.3 years (range interquartile 43.9–60.6). The underlying diseases were: acute leukemia (39), non-Hodgkin lymphoma (6), Hodgkin disease (3), multiple myeloma (1) and myelodysplastic syndrome (1) (Table 1). UEDVT was diagnosed in 19 patients (38%) during chemotherapy induction phase, in 6 (12%) at disease relapse, in 15 (30%) during disease remission, in 2 (4%) in the terminal phase of the disease and in 8 (16%) during an allogeneic stem

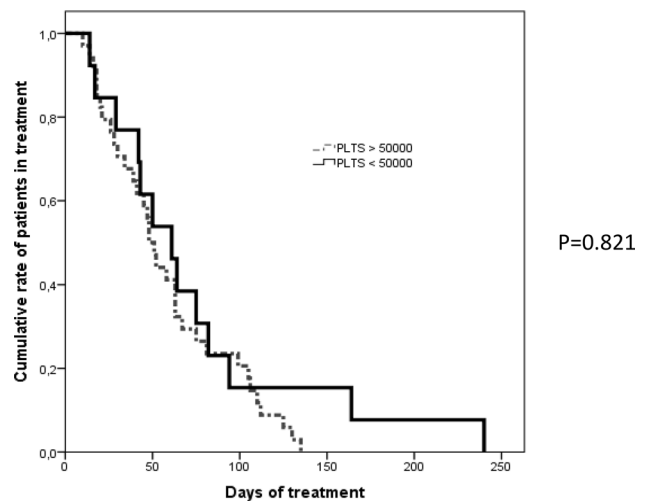
**Table 1** Patients' characteristics

Patients	50
Male	29
Female	21
Age (median, range)	53.3 (43.9–60.6)
Acute leukemia	39
Non-Hodgkin lymphoma	6
Hodgkin disease	3
Multiple myeloma	1
Myelodysplastic syndrome	1

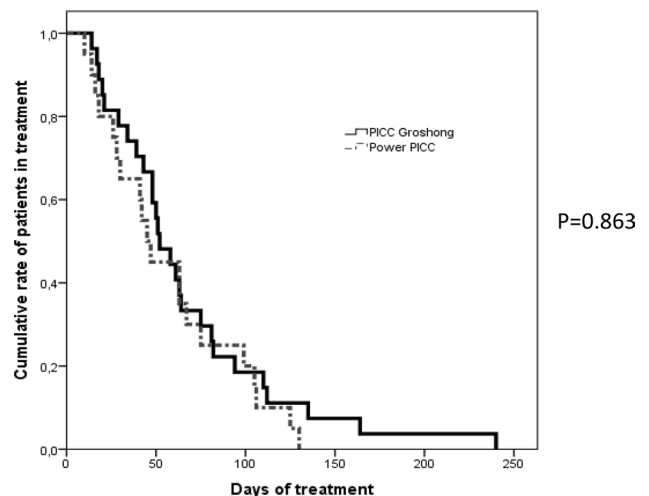
**Table 2** UEDVT diagnosis and treatment

UEDVT onset phase		
Chemotherapy induction phase		19
Disease relapse		6
Disease remission		15
Terminal phase		2
Allogeneic stem cell transplant		8
	Patients	Median plts
Platelets $\geq 50 \times 10^9/l$ (group 1)	36	$155 \times 10^9/l$
Platelets $30\text{--}50 \times 10^9/l$ (group 2)	8	$38 \times 10^9/l$
Platelets $< 30 \times 10^9/l$ (group 3)	6	$19 \times 10^9/l$

cell transplant. Thirty-six patients (72%) were in group 1 with a median platelet count of  $155 \times 10^9/l$  (range interquartile  $105\text{--}287 \times 10^9/l$ ). Eight patients (16%) were in group 2 with a median platelet count of  $38 \times 10^9/l$  (range interquartile  $37\text{--}43 \times 10^9/l$ ). Six patients (12%) were in group 3 with a median platelet count of  $19 \times 10^9/l$  (range interquartile  $13\text{--}27 \times 10^9/l$ ) (Table 2). A peripheral venous access was obtained through the basilic vein in 39 cases (78%) and through the brachial vein in 11 cases (22%). No patient had a prior history of VTE and none received antithrombotic prophylaxis for DVT after PICC placement. In group 1, 31 patients received therapeutic doses of LMWH and 5 fondaparinux 7.5 mg daily. In group 2, 7 patients received 50% reduced doses of LMWH and 1 fondaparinux 5 mg/day. In group 3, 2 patients received reduced doses of LMWH after platelet transfusion and 4 were not treated until platelets were  $\geq 30 \times 10^9/l$  (after an average of 6.7 days) and thereafter started reduced doses of LMWH. During the treatment period, 6 patients passed from group 2 to group 1 and increased LMWH doses, while 3 patients passed from group 1 to group 2 requiring a LMWH dose reduction because of a worsening thrombocytopenia. Twenty-seven (54%) were Groshong PICCs, while 23 (46%) were Power PICCs. UEDVT was diagnosed after a median of 34.5 days from PICC placement. Anticoagulant therapy was discontinued in 2 patients of group 1 due to hemorrhagic cystitis with hematuria related to chemotherapy. We observed 2 thrombotic events during anticoagulant therapy (thrombosis of the popliteal vein) in patients of group 2. PICCs were not removed for the UEDVT. The median duration of the anticoagulant therapy was 51 days (range interquartile 28–90) in group 1 and 50 days (range interquartile 31–83) in group 2 (p 0.821) (Fig. 1). The median therapy length was 56 days (range interquartile 35–83) in patients with a Groshong PICC and 45 days (range 26–75) in patients with a Power PICC (p 0.863) (Fig. 2).



**Fig. 1** Differences in terms of therapy length between patients with a platelet count  $\geq 50 \times 10^9/l$  and patients with a platelet count  $< 50 \times 10^9/l$



**Fig. 2** Differences in terms of therapy length between patients who had a Groshong PICC and patients who had a Power PICC

## Discussion

PICCs have optimized the possibility of administering high-dose chemotherapy in patients with onco-hematological diseases, preventing the effects of chemotherapies on the vessels and the consequences deriving from a possible extravasation. They also provide a safe peripheral access through which patients can receive supportive therapies. Although rare, UEDVT may arise following the insertion of PICCs and represent an important adverse event. Furthermore, UEDVT can occur also in thrombocytopenic patients: in fact, the presence of a thrombocytopenia is not always protective against VTE [5, 13]; in patients with hematological neoplasms other factors related to the disease and therapy may activate the coagulation cascade leading to thrombosis as well as to the reduction of the physiological anticoagulants. The optimal management of VTE treatment in onco-hematological patients with thrombocytopenia remains challenging and the standard of care is LMWH considered safer due to the lower incidence of bleeding and easiness in dosing. The more recent recommendations suggest full dose anticoagulant therapy when the platelet count is  $\geq 50 \times 10^9/l$ . In patients with a platelet count  $< 50 \times 10^9/l$ , the optimal treatment remains unknown: in these cases, full dose anticoagulant therapy is considered unsafe, due to a higher bleeding risk, and a reduced dose of LMWH or fondaparinux is generally preferred. In cases of severe thrombocytopenia (platelets  $< 30 \times 10^9/l$ ) consensus-based guidelines acknowledge the limitations in the currently available data and recommend that treatment decisions are taken on a case-by-case basis [5, 14] ranging from prophylactic doses of heparin to platelet transfusion or clinical observation. Purpose of our study was to evaluate the efficacy and safety of different doses of LMWH or fondaparinux according to the platelet count for the treatment of PICC-related UEDVT in a cohort of patients with hematological malignancies and undergoing intensive chemotherapies. In our cases, UEDVT proved to be a rare PICC-related adverse event with an incidence of 0.32% case/year. Fourteen patients (28%) had a platelet count  $< 50 \times 10^9/l$  at the time of thrombosis occurrence. We observed that the reduced doses of LMWH or fondaparinux, performed in patients with a platelet count between  $50 \times 10^9/l$  and  $30 \times 10^9/l$ , were effective and safe similarly to the full doses in patients with platelets  $\geq 50 \times 10^9/l$ . Moreover, the reduced doses of LMWH or fondaparinux in patients with a platelet count  $< 50 \times 10^9/l$  did not cause an increased risk of UEDVT relapses. In our series, we observed 2 thrombotic complications occurred in different sites, probably due to the underlying diseases. Similar results have been reported in observational studies [11, 15]. In a retrospective study

conducted in 214 patients affected by acute leukemia, 23 developed a catheter-related thrombosis, of which 14 were treated with low doses LMWH due to severe thrombocytopenia and no recurrent VTE were observed, further underlying that a reduced dose of LMWH may be effective in patients with concurrent thrombocytopenia [16]. We also documented that therapeutic doses of LMWH or fondaparinux administered in patients with a mild thrombocytopenia do not lead to a significant increase in bleeding risk: the 2 hemorrhagic cystitis observed were related to chemotherapy toxicity. In addition, we did not observe any differences in terms of time to thrombosis resolution, between group 1 and group 2 (51 vs 50 days), and between patients with a Groshong PICC and those with a Power PICC (56 vs 45 days). In conclusion, although PICC-related adverse events are uncommon, they represent a VTE risk factor in cancer patients. UEDVT represent one of the most challenging complications, especially when occurring in thrombocytopenic patients. Our study confirms that in the event of a PICC-related UEDVT in patients with a moderate thrombocytopenia ( $< 50 \times 10^9/l$  and  $\geq 30 \times 10^9/l$ ) reduced doses LMWH or fondaparinux are safe and effective in this subset of patients at a higher bleeding risk. However, we are aware that the present sample was relatively low and thus this final consideration warrants further confirmations in larger cohorts of patients.

## Compliance with ethical standards

**Conflict of interest** The authors don't have any conflict of interest.

**Ethical approval** All procedures performed in studies involving human participants were in accordance with the ethical standards of the institutional and/or national research committee and with the 1964 Helsinki declaration and its later amendments or comparable ethical standards.

**Informed consent** Informed consents were retrospectively obtained from patients or familiars for being included in the study.

## References

1. Evans RS, Sharp JH, Linford LH, Lloyd JF, Woller SC, Stevens SM, Elliott CG, Tripp JS, Jones SS, Weaver LK (2013) Reduction of peripherally inserted central catheter-associated DVT. *Chest* 143(3):627–633
2. Geerts W (2014) Central venous catheter-related thrombosis. *Hematology* 2014(1):306–311
3. Curto-Garcia N, Garcia-Suàrez J, Callejas Chavarria M, Gil Fernández JJ, Martín Guerrero Y, MagroMazo E, Marcellini Antonio S, Juárez LM, Gutierrez I, Arranz JJ, Montalvo I, Elvira C, Dominguez P, Diaz MT, Burgaleta C (2016) A team-based multidisciplinary approach to managing peripherally inserted central catheter complications in high-risk haematological patients: a prospective study. *Support Care Cancer* 24(1):93–101

4. Chopra V, Anand S, Hickner A, Buist M, Rogers MA, Saint S, Flanders SA (2013) Risk of venous thromboembolism associated with peripherally inserted central catheters: a systematic review and meta-analysis. *Lancet* 382(9889):311–325
5. Khanal N, Bociek RG, Chen B, Vose JM, Armitage JO, Bierman PJ, Maness LJ, Lunning MA, Gundabolu K, Bhatt VR (2016) Venous thromboembolism in patients with hematologic malignancy and thrombocytopenia. *Am J Hematol.* 91(11):E468–E472
6. Khorana AA, Connolly GC (2009) Assessing risk of venous thromboembolism in the patient with cancer. *J Clin Oncol.* 27(29):4839–4847
7. Louzada ML, Majeed H, Dao V, Wells PS (2011) Risk of recurrent venous thromboembolism according to malignancy characteristics in patients with cancer-associated thrombosis: a systematic review of observational and intervention studies. *Blood Coagul Fibrinolysis.* 22(2):86–91
8. Napolitano M, Saccullo G, Marietta M, Carpenedo M, Castaman G, Cerchiara E, Chistolini A, Contino L, De Stefano V, Falanga A, Federici AB, Rossi E, Santoro R, Siragusa S, Gruppo ItalianoMallatie Ematologiche dell'Adulto (GIMEMA) Working Party on Thrombosis and Hemostasis, De Stefano V, Falanga A, Toso A, Avvisati G, Carpenedo M, Federici AB, Marietta M, Napolitano M, Rossi E, Santoro C, Castaman G, Cerchiara E, Chistolini A, Contino L, Mazzucconi MG, Nichele I, Russo L, Santi R, Santoro RC, Siragusa S, Tagariello G, (2019) Platelet cut-off for anticoagulant therapy in thrombocytopenic patients with blood cancer and venous thromboembolism: an expert consensus. *Blood Transfus.* 17(3):171–180
9. Herishanu Y, Misgav M, Kirgner I, Ben-Tal O, Eldor A, Naparstek E (2004) Enoxaparin can be used safely in patients with severe thrombocytopenia due to intensive chemotherapy regimens. *Leuk Lymphoma.* 45(7):1407–1411
10. Drakos PE, Nagler A, Or R, Gillis S, Slavin S, Eldor A (1992) Low molecular weight heparin for Hickman catheter-induced thrombosis in thrombocytopenic patients undergoing bone marrow transplantation. *Cancer* 70(7):1895–1898
11. Mantha S, Miao Y, Wills J, Parameswaran R, Soff GA (2017) Enoxaparin dose reduction for thrombocytopenia in patients with cancer: a quality assessment study. *J Thromb Thrombolysis.* 43(4):514–518
12. Carrier M, Khorana AA, Zwicker JI, Noble S, Lee AY (2013) Subcommittee on haemostasis and malignancy for the SSC of the ISTH. Management of challenging cases of patients with cancer-associated thrombosis and bleeding: guidance from the SSC of the ISTH. *J Thromb Haemost.* 11(9):1760–1765
13. Gerber DE, Segal JB, Levy MY, Kane J, Jones RJ, Streiff MB (2008) The incidence of and risk factors for venous thromboembolism (VTE) and bleeding among 1514 patients undergoing hematopoietic stem cell transplantation: implications for VTE prevention. *Blood* 112(3):504–510
14. Farge D, Debourdeau P, Beckers M, Baglin C, Bauersachs RM, Brenner B, Brillhante D, Falanga A, Gerotzafias GT, Haim N, Kakkak AK, Khorana AA, Lecumberri R, Mandala M, Marty M, Monreal M, Mousa SA, Noble S, Pabinger I, Prandoni P, Prins MH, Qari MH, Streiff MB, Syrigos K, Bounameaux H, Büller HR (2013) International clinical practice guidelines for the treatment and prophylaxis of venous thromboembolism in patients with cancer. *J Thromb Haemost.* 11(1):56–70
15. Kopolovic I, Lee AY, Wu C (2015) Management and outcomes of cancer-associated venous thromboembolism in patients with concomitant thrombocytopenia: a retrospective cohort study. *Ann Hematol.* 94(2):329–336
16. Htun KT, Ma MJ, Lee AY (2018) Incidence and outcomes of catheter related thrombosis (CRT) in patients with acute leukemia using a platelet-adjusted low molecular weight heparin regimen. *J Thromb Thrombolysis* 46(3):386–392

**Publisher's Note** Springer Nature remains neutral with regard to jurisdictional claims in published maps and institutional affiliations.